Obtaining the 20 Standard Transesophageal Echocardiography Views

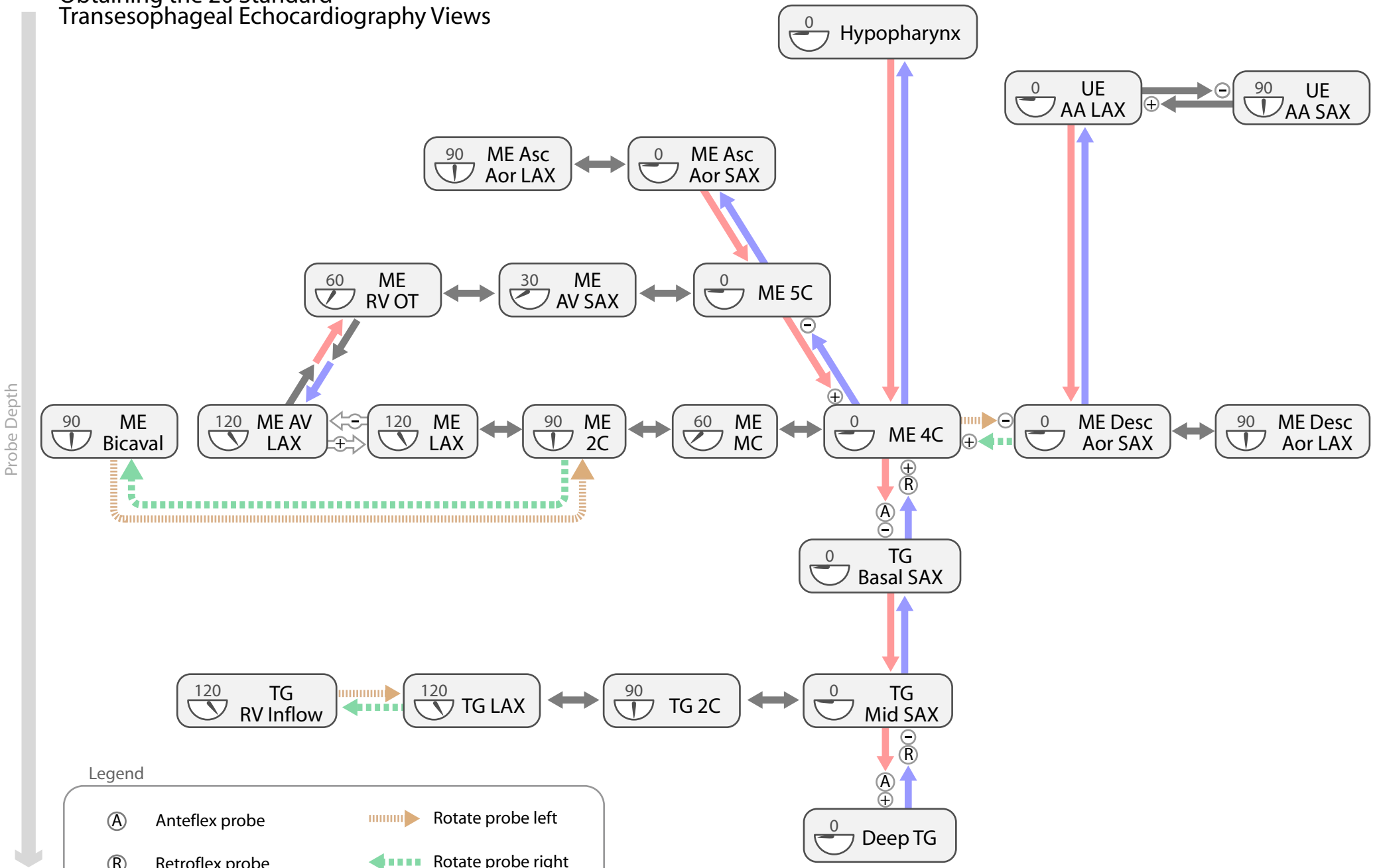

Legend

Ⓐ	Anteflex probe		Rotate probe left
Ⓡ	Retroflex probe		Rotate probe right
⊖	Decrease omniplane depth (display depth)		Increase probe depth
⊕	Increase omniplane depth (display depth)		Decrease probe depth
↔	Change omniplane angle	90	Omniplane angle

2C - Two Chamber
4C - Four Chamber
5C - Five Chamber
AA - Aortic Arch
AV - Aortic Valve

Asc Aor - Ascending Aortic
Desc Aor - Descending Aortic
OT - Outflow Tract (Inflow-Outflow)
LAX - Long Axis
MC - Mitral Commissural

ME - Mid Esophageal
RV - Right Ventricle
SAX - Short Axis
TG - Transgastric
UE - Upper Esophageal

©Toronto General Hospital Department of Anesthesia and Pain Management 2008